Review Articles

Medical Progress

SMALL-VESSEL VASCULITIS

J. CHARLES JENNETTE, M.D., AND RONALD J. FALK, M.D.

VASCULITIS is inflammation of vessel walls. It has many causes, although they result in only a few histologic patterns of vascular inflammation. Vessels of any type in any organ can be affected, a fact that results in a wide variety of signs and symptoms. These protean clinical manifestations, combined with the etiologic nonspecificity of the histologic lesions, complicate the diagnosis of specific forms of vasculitis. This is problematic because different vasculitides with indistinguishable clinical presentations have very different prognoses and treatments. For example, a patient with purpura, nephritis, and abdominal pain caused by Henoch–Schönlein purpura usually has a good prognosis and needs only supportive care, whereas a patient with purpura, nephritis, and abdominal pain caused by microscopic polyangiitis is likely to go on to life-threatening organ failure if not treated promptly and appropriately.

In recent years there has been substantial progress in identifying the attributes of specific types of vasculitis that allow accurate diagnosis. One approach to classifying noninfectious vasculitides categorizes them, in part, on the basis of the predominant type of vessel affected (Tables 1 and 2 and Fig. 1).[1] There is, however, substantial overlap among different vasculitides, and the type of vessel involved is merely one of many features that must be determined before a diagnosis can be rendered.

This review will focus on noninfectious necrotizing small-vessel vasculitis, beginning with a history of the discovery of the major categories of the disease and concluding with a review of its diagnosis and treatment. Small-vessel vasculitis is defined as vasculitis that affects vessels smaller than arteries, such as arterioles, venules, and capillaries. Important categories of the disease are listed in Table 1. It is important to note that small-vessel vasculitis sometimes, but not always, also affects arteries, and thus the vascular distribution overlaps with that of the medium-sized-vessel and large-vessel vasculitides (Fig. 1).

HISTORICAL BACKGROUND

Two paths of investigation, which eventually intersected, led to our current understanding of small-vessel vasculitis. One focused on necrotizing arteritis, and the other on purpura.

Discovery and Categorization of Necrotizing Arteritis

Kussmaul and Maier published the first definitive report of a patient with necrotizing arteritis in 1866.[2] They described a patient with fever, anorexia, muscle weakness, paresthesias, myalgias, abdominal pain, and oliguria who was found to have nodular inflammatory lesions in medium-sized and small arteries throughout the body. They called this condition periarteritis nodosa, which evolved into the more pathologically correct name polyarteritis nodosa. For more than 50 years (and unfortunately even today in some settings), any patient with necrotizing arteritis was given a diagnosis of polyarteritis nodosa.

By the 1950s, many investigators had realized that there were a number of clinically and pathologically distinct forms of arteritis and that arteritis often occurred as a component of a vasculitis in which many if not most of the involved vessels were smaller than arteries (e.g., dermal venules, mucosal arterioles, glomerular capillaries, and pulmonary alveolar capillaries).[3-7] Zeek et al. called this form of vasculitis with small-vessel involvement "hypersensitivity angiitis,"[5,6] whereas Davson et al.[4] and Godman and Churg[7] referred to it as the "microscopic form of periarteritis." In 1994, the term "microscopic polyangiitis" was advocated by an international consensus conference on vasculitis nomenclature,[1] and it will be used in this review. "Microscopic polyangiitis" is preferable as a name to "microscopic polyarteritis," because many patients with this type of vasculitis have disease confined to arterioles, venules, and capillaries and thus have no arteritis.

Also by the 1950s, two variants of vasculitis with associated necrotizing granulomatous inflammation had been recognized — i.e., Wegener's granulomatosis and Churg–Strauss syndrome. Wegener's gran-

From the Departments of Pathology and Laboratory Medicine (J.C.J.) and Medicine (R.J.F.), University of North Carolina at Chapel Hill, Chapel Hill. Address reprint requests to Dr. Jennette at CB#7525, Department of Pathology and Laboratory Medicine, University of North Carolina, Chapel Hill, NC 27599-7525.

©1997, Massachusetts Medical Society.

Downloaded from www.nejm.org at UNIVERSITY HOSPITALS OF CLEVELAND on May 26, 2006 .
Copyright © 1997 Massachusetts Medical Society. All rights reserved.

TABLE 1. MAJOR CATEGORIES OF NONINFECTIOUS VASCULITIS.*

Large-vessel vasculitis
Giant-cell arteritis
Takayasu's arteritis
Medium-sized-vessel vasculitis
Polyarteritis nodosa
Kawasaki's disease
Primary granulomatous central nervous system vasculitis
Small-vessel vasculitis
ANCA-associated small-vessel vasculitis
Microscopic polyangiitis
Wegener's granulomatosis
Churg–Strauss syndrome
Drug-induced ANCA-associated vasculitis
Immune-complex small-vessel vasculitis
Henoch–Schönlein purpura
Cryoglobulinemic vasculitis
Lupus vasculitis
Rheumatoid vasculitis
Sjögren's syndrome vasculitis
Hypocomplementemic urticarial vasculitis
Behçet's disease
Goodpasture's syndrome
Serum-sickness vasculitis
Drug-induced immune-complex vasculitis
Infection-induced immune-complex vasculitis
Paraneoplastic small-vessel vasculitis
Lymphoproliferative neoplasm-induced vasculitis
Myeloproliferative neoplasm-induced vasculitis
Carcinoma-induced vasculitis
Inflammatory bowel disease vasculitis

*Vascular inflammation is categorized as either infectious vasculitis, which is caused by the direct invasion of vessel walls by pathogens (e.g., rickettsial organisms in Rocky Mountain spotted fever), or noninfectious vasculitis, which is not caused by the direct invasion of vessel walls by pathogens (although infections can indirectly induce noninfectious vasculitis — e.g., by generating pathogenic immune complexes). ANCA denotes antineutrophil cytoplasmic autoantibodies.

TABLE 2. NAMES AND DEFINITIONS OF VASCULITIS ADOPTED BY THE CHAPEL HILL CONSENSUS CONFERENCE ON THE NOMENCLATURE OF SYSTEMIC VASCULITIS.*

LARGE-VESSEL VASCULITIS	
Giant-cell (temporal) arteritis	Granulomatous arteritis of the aorta and its major branches, with a predilection for the extracranial branches of the carotid artery. *Often involves the temporal artery. Usually occurs in patients more than 50 years old and is often associated with polymyalgia rheumatica.*
Takayasu's arteritis	Granulomatous inflammation of the aorta and its major branches. *Usually occurs in patients younger than 50.*
MEDIUM-SIZED-VESSEL VASCULITIS	
Polyarteritis nodosa	Necrotizing inflammation of medium-sized or small arteries without glomerulonephritis or vasculitis in arterioles, capillaries, or venules.
Kawasaki's disease	Arteritis involving large, medium-sized, and small arteries and associated with mucocutaneous lymph node syndrome. *Coronary arteries are often involved. Aorta and veins may be involved. Usually occurs in children.*
SMALL-VESSEL VASCULITIS	
Wegener's granulomatosis†	Granulomatous inflammation involving the respiratory tract and necrotizing vasculitis affecting small-to-medium-sized vessels (e.g., capillaries, venules, arterioles, and arteries). *Necrotizing glomerulonephritis is common.*
Churg–Strauss syndrome†	Eosinophil-rich and granulomatous inflammation involving the respiratory tract and necrotizing vasculitis affecting small-to-medium-sized vessels and associated with asthma and eosinophilia.
Microscopic polyangiitis†	Necrotizing vasculitis with few or no immune deposits affecting small vessels (capillaries, venules, or arterioles). *Necrotizing arteritis involving small and medium-sized arteries may be present. Necrotizing glomerulonephritis is very common. Pulmonary capillaritis often occurs.*
Henoch–Schönlein purpura	Vasculitis with IgA-dominant immune deposits affecting small vessels (capillaries, venules, or arterioles). *Typically involves skin, gut, and glomeruli and is associated with arthralgias or arthritis.*
Essential cryoglobulinemic vasculitis	Vasculitis with cryoglobulin immune deposits affecting small vessels (capillaries, venules, or arterioles) and associated with cryoglobulins in serum. *Skin and glomeruli are often involved.*
Cutaneous leukocytoclastic angiitis	Isolated cutaneous leukocytoclastic angiitis without systemic vasculitis or glomerulonephritis.

*This table is adapted with modifications from Jennette et al.,[1] with the permission of the publisher. "Large vessel" refers to the aorta and the largest arterial branches directed toward major body regions (e.g., to the extremities and the head and neck). "Medium-sized vessel" refers to the main visceral arteries and their branches. "Small vessel" refers to arterioles, venules, and capillaries, although arteries, especially small arteries, may be included in this category of vasculitis. Note that all three categories affect arteries, but only small-vessel vasculitis has a predilection for vessels smaller than arteries.

†These vasculitides are associated with antineutrophil cytoplasmic autoantibodies (ANCA).

ulomatosis was initially reported by Klinger in 1931[8] and later described in more detail by Wegener.[9] The definitive description was provided in 1954 by Godman and Churg, who identified a triad of features: systemic necrotizing "angiitis," necrotizing inflammation of the respiratory tract, and necrotizing glomerulonephritis.[7] Subsequently, patients with limited expressions of the disease were recognized — for example, patients with no glomerulonephritis.[10]

Churg and Strauss, in 1951, described 13 patients who had asthma, eosinophilia, granulomatous inflammation, necrotizing systemic vasculitis, and necrotizing glomerulonephritis.[11] This disease is now called Churg–Strauss syndrome.

In their landmark 1954 article,[7] Godman and Churg concluded that Wegener's granulomatosis, Churg–Strauss syndrome, and the "microscopic form of periarteritis" (microscopic polyangiitis) are closely related and distinct from polyarteritis nodosa. As

Downloaded from www.nejm.org at UNIVERSITY HOSPITALS OF CLEVELAND on May 26, 2006 .
Copyright © 1997 Massachusetts Medical Society. All rights reserved.

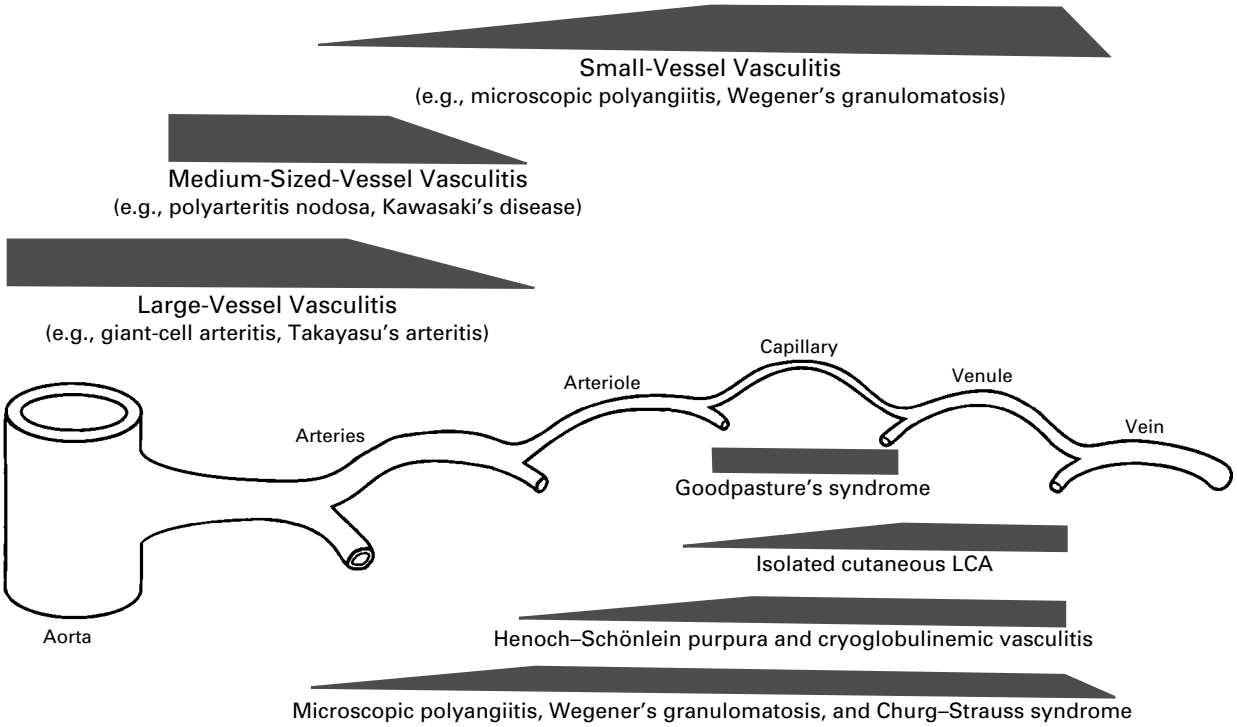

Figure 1. Preferred Sites of Vascular Involvement by Selected Vasculitides.
The widths of the trapezoids indicate the frequencies of involvement of various portions of the vasculature. LCA denotes leukocytoclastic angiitis.

will be discussed later, this conclusion is supported by recent immunologic observations.

Pathological evaluation of patients with arterial inflammation demonstrated that histologically indistinguishable necrotizing arteritis (Fig. 2) is shared by a variety of vasculitides, including polyarteritis nodosa, Kawasaki's disease, microscopic polyangiitis, Wegener's granulomatosis, and Churg–Strauss syndrome. However, whereas medium-sized-vessel vasculitis, such as polyarteritis nodosa and Kawasaki's disease, involves predominantly if not exclusively arteries, small-vessel vasculitis, such as microscopic polyangiitis and Wegener's granulomatosis, may or may not include arteritis but virtually always affects vessels smaller than arteries (Fig. 1). By the 1980s, this concept of "small-vessel vasculitides" that are distinct from vasculitides affecting predominantly medium-sized and large arteries was well established.[12]

Historical Description of the Manifestations of Venulitis and Capillaritis

Purpura (Fig. 3) was the first manifestation of vasculitis in vessels smaller than arteries to be extensively investigated. In 1808, Willan clearly distinguished purpura caused by systemic febrile infections from noninfectious purpura.[13] He noted that noninfectious purpura had a predilection for the lower extremities, was characterized by recurrent groups of lesions, and could be associated with systemic disease. Over the next century, Schönlein,[14] Henoch,[15,16] Osler,[17,18] and others elucidated a broad spectrum of signs and symptoms that were associated with purpura, and thus with small-vessel vasculitis, including arthritis, peripheral neuropathy, abdominal pain, pulmonary hemorrhage, epistaxis, iritis, and nephritis. Osler recognized that these clinical manifestations were caused by necrotizing inflammation in small vessels.[17,18]

In 1919, Goodpasture reported a patient with pulmonary hemorrhage and rapidly progressive glomerulonephritis who had vasculitis affecting small splenic arteries, arterioles in the gut, pulmonary capillaries, and glomerular capillaries.[19] This pulmonary–renal vasculitic syndrome is now recognized to be a manifestation of multiple pathogenetically distinct forms of small-vessel vasculitis. The designation "Goodpasture's syndrome" now is usually restricted to patients with vascular injury caused by antibodies to glomerular basement membrane,[20] even though most patients with pulmonary–renal vasculitic syndrome have some other small-vessel vasculitis[21,22]

Downloaded from www.nejm.org at UNIVERSITY HOSPITALS OF CLEVELAND on May 26, 2006 .
Copyright © 1997 Massachusetts Medical Society. All rights reserved.

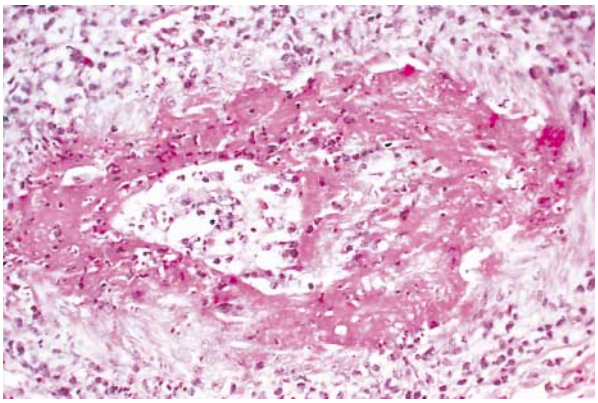

Figure 2. Necrotizing Arteritis in a Small Epineural Artery in a Nerve-Biopsy Specimen from a Patient with Microscopic Polyangiitis.

The muscularis is completely destroyed by fibrinoid necrosis that extends into the perivascular tissue. (Hematoxylin and eosin, ×300.)

Figure 3. Purpura on the Lower Leg of a Patient Found to Have Leukocytoclastic Angiitis in a Skin-Biopsy Specimen.

There are also several darker areas of necrosis. (Photograph kindly provided by Robert A. Briggaman.)

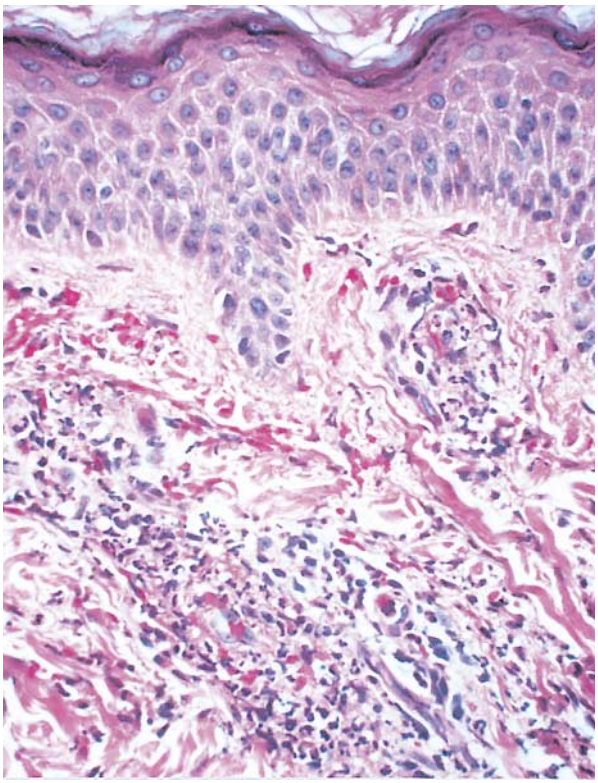

Figure 4. Leukocytoclastic Angiitis in a Skin-Biopsy Specimen from a Patient with Purpura.

There is extensive karyorrhexis of the vascular and perivascular leukocytes (leukocytoclasia). (Hematoxylin and eosin, ×500.)

and the vasculitis in Goodpasture's patient was probably not caused by these antibodies.[23]

By the 1950s, the histologic features of necrotizing vasculitis in venules and other small vessels had been well described, including the conspicuous leukocytoclasia, which prompted the etiologically nonspecific pathological term "leukocytoclastic angiitis"[24,25] (Fig. 4). The similarity of this pattern of injury to the Arthus reaction, as well as an association between some cases of necrotizing vasculitis and exposure to drugs and foreign proteins, led to the contention that some if not most necrotizing vasculitides were hypersensitivity diseases.[5,6,12,18,24-28]

The ability to identify pathogenic antibodies in tissue and serum by immunofluorescence microscopy led to discoveries that allowed the categorization of certain small-vessel vasculitides — for example, recognition of antibodies to glomerular basement membrane as the cause of some cases of pulmonary–renal vasculitic syndrome[29-31]; the identification of a subgroup of patients with purpura, arthralgias, and glomerulonephritis caused by the deposition of cryoglobulin[32]; the identification of vascular IgA de-

Downloaded from www.nejm.org at UNIVERSITY HOSPITALS OF CLEVELAND on May 26, 2006 .
Copyright © 1997 Massachusetts Medical Society. All rights reserved.

posits as a marker for Henoch–Schönlein purpura[33]; and the detection of pathogen-derived antigens and cognate antibodies in the vessels of patients with small-vessel vasculitis that is associated with infections such as hepatitis B.[34] These and other observations supported the concept of an immune-complex pathogenesis for at least some forms of small-vessel vasculitis; however, evaluation of a wide range of vasculitides failed to document a high frequency of vascular immune complexes in many important categories, including Wegener's granulomatosis, microscopic polyangiitis, and Churg–Strauss syndrome.[21,35,36] This absence or paucity of vascular immune deposits distinguished the "pauci-immune" vasculitides from the immune-complex vasculitides, but categorization based on negative data was unsettling. This problem was resolved, in part, with the discovery of antineutrophil cytoplasmic autoantibodies (ANCA).

Antineutrophil Cytoplasmic Autoantibodies

In 1982, Davies and his associates reported having detected antibodies that reacted with neutrophil cytoplasm in eight patients with pauci-immune necrotizing glomerulonephritis and small-vessel vasculitis.[37] Two years later, Hall et al. confirmed this observation in four patients with small-vessel vasculitis.[38] These first two articles on ANCA did not receive much attention, but a 1985 article by van der Woude and his collaborators generated substantial interest by suggesting that detection of ANCA was a useful diagnostic and prognostic marker for Wegener's granulomatosis.[39] Subsequent studies revealed that ANCA are closely associated with three major categories of small-vessel vasculitis: Wegener's granulomatosis, microscopic polyangiitis, and Churg–Strauss syndrome[40-42] — the same three diseases that Godman and Churg had concluded were related in their 1954 publication.[7]

ANCA are specific for antigens in neutrophil granules and monocyte lysosomes. They can be detected with indirect immunofluorescence microscopy by using alcohol-fixed neutrophils as substrate. This produces two major staining patterns: cytoplasmic ANCA and perinuclear ANCA. Specific immunochemical assays demonstrate two major antigen specificities in patients with vasculitis: antimyeloperoxidase (MPO-ANCA)[43] and antiproteinase 3 (PR3-ANCA).[44-47] In patients with vasculitis, approximately 90 percent of cytoplasmic ANCA are PR3-ANCA and approximately 90 percent of perinuclear ANCA are MPO-ANCA. Either ANCA specificity may occur in a patient with any type of ANCA-associated small-vessel vasculitis; however, most patients with Wegener's granulomatosis have PR3-ANCA (cytoplasmic ANCA), whereas most patients with microscopic polyangiitis or Churg–Strauss syndrome have MPO-ANCA (perinuclear ANCA).[41-43] It is very important to realize that approximately 10 percent of patients with typical Wegener's granulomatosis or microscopic polyangiitis have negative assays for ANCA; thus, ANCA negativity does not completely rule out these diseases. In addition, the specificity of ANCA positivity is not absolute; thus, a positive result is not diagnostic for an ANCA-associated vasculitis, especially if the result of an indirect immunofluorescence assay has not been confirmed by a more specific immunochemical assay for PR3-ANCA or MPO-ANCA.[48]

The addition of serologic tests for ANCA to the diagnostic armamentarium provided a positive marker for certain types of pauci-immune small-vessel vasculitis. Testing for ANCA, along with other immunopathologic markers such as vascular IgA deposits and serum cryoglobulins, facilitates the diagnostic categorization of small-vessel vasculitis (Table 3).

DIAGNOSIS AND TREATMENT OF SMALL-VESSEL VASCULITIS

The first step in diagnosis is to recognize that small-vessel vasculitis is present, and the second, more difficult step is to determine the specific type of the disease. The signs and symptoms of small-vessel vasculitis are extremely varied, and many are shared by all small-vessel vasculitides. Diagnosis requires assessment of both the presence of prerequisite features and, just as important, the absence of incompatible features (Table 3). Accurate diagnosis is important, because the prognosis and appropriate treatment are different for different types of small-vessel vasculitis.

General Signs and Symptoms of Small-Vessel Vasculitis

Constitutional signs and symptoms, such as fever, myalgias, arthralgias, and malaise, often accompany small-vessel vasculitis. Many patients describe a "flu-like" syndrome early in the course of their disease. Arthralgias are migratory and affect both small and large joints, with evidence of synovitis in 10 to 20 percent of patients. Vessels in the skin, respiratory tract, kidneys, gut, peripheral nerves, and skeletal muscle are often involved, but the frequencies vary among categories of small-vessel vasculitis (Table 4). For example, Wegener's granulomatosis and microscopic polyangiitis are more likely to cause pulmonary–renal syndrome, whereas cryoglobulinemic vasculitis and Henoch–Schönlein purpura are more likely to cause dermal–renal syndrome.

The most common cutaneous lesion is leukocytoclastic angiitis (Fig. 4), which typically causes purpura, sometimes with slight focal necrosis and ulceration, that preferentially affects the lower extremities (Fig. 3).[27,66] Necrotizing arteritis in small dermal and subcutaneous arteries causes erythematous tender nodules, focal necrosis, ulceration, and livedo reticularis. Patients with Wegener's granulomatosis and Churg–Strauss syndrome may also have cutaneous

Downloaded from www.nejm.org at UNIVERSITY HOSPITALS OF CLEVELAND on May 26, 2006 .
Copyright © 1997 Massachusetts Medical Society. All rights reserved.

TABLE 3. DIFFERENTIAL DIAGNOSTIC FEATURES OF SEVERAL FORMS OF SMALL-VESSEL VASCULITIS.

FEATURE	HENOCH–SCHÖNLEIN PURPURA	CRYOGLOBULINEMIC VASCULITIS	MICROSCOPIC POLYANGIITIS	WEGENER'S GRANULOMATOSIS	CHURG–STRAUSS SYNDROME
Signs and symptoms of small-vessel vasculitis*	+	+	+	+	+
IgA-dominant immune deposits	+	−	−	−	−
Cryoglobulins in blood and vessels	−	+	−	−	−
ANCA in blood	−	−	+	+	+
Necrotizing granulomas	−	−	−	+	+
Asthma and eosinophilia	−	−	−	−	+

*All of these small-vessel vasculitides can manifest any or all of the shared features of small-vessel vasculitides, such as purpura, nephritis, abdominal pain, peripheral neuropathy, myalgias, and arthralgias. Each is distinguished by the presence and, just as important, the absence of certain specific features. ANCA denotes antineutrophil cytoplasmic autoantibodies.

TABLE 4. APPROXIMATE FREQUENCY OF ORGAN-SYSTEM MANIFESTATIONS IN SEVERAL FORMS OF SMALL-VESSEL VASCULITIS.*

ORGAN SYSTEM	HENOCH–SCHÖNLEIN PURPURA	CRYOGLOBULINEMIC VASCULITIS	MICROSCOPIC POLYANGIITIS	WEGENER'S GRANULOMATOSIS	CHURG–STRAUSS SYNDROME
			percent		
Cutaneous	90	90	40	40	60
Renal	50	55	90	80	45
Pulmonary	<5	<5	50	90	70
Ear, nose, and throat	<5	<5	35	90	50
Musculoskeletal	75	70	60	60	50
Neurologic	10	40	30	50	70
Gastrointestinal	60	30	50	50	50

*Approximate frequencies are estimated from data in previous reports.[49-65]

nodules caused by granulomatous inflammation. Urticaria can be a manifestation of small-vessel vasculitis, especially when there is immune-complex deposition with extensive complement activation. Unlike nonvasculitic allergic urticaria, vasculitic urticaria lasts for more than a day, may evolve into purpuric lesions, and may be accompanied by hypocomplementemia.[67]

Peripheral neuropathy, especially mononeuritis multiplex, is the most common neurologic manifestation.[68,69] This is caused by inflammation of small epineural arteries and arterioles, resulting in neural ischemia. Both sensory and motor fibers are involved. Central nervous system disease usually results from involvement of the meningeal vessel.

Necrotizing inflammation in small arteries, arterioles, and venules in skeletal muscle and viscera causes pain and elevations of tissue enzymes in the blood. Ischemic ulceration in the gut causes not only abdominal pain but also blood in the stool. Intussusception and perforation of the gut and pancreatitis are serious complications.

Respiratory tract disease is frequent in ANCA-associated small-vessel vasculitis and in Goodpasture's syndrome but is rare in immune-complex small-vessel vasculitis, such as Henoch–Schönlein purpura and cryoglobulinemic vasculitis (Table 4). Inflammation of the upper respiratory tract is frequent in small-vessel vasculitis associated with ANCA. Pulmonary manifestations range from fleeting focal infiltrates to massive pulmonary hemorrhage and hemoptysis caused by hemorrhagic alveolar capillaritis (Fig. 5), the most life-threatening feature of small-vessel vasculitis. Granulomatous pulmonary inflammation of Wegener's granulomatosis and Churg–Strauss syndrome cause nodular and occasionally

Downloaded from www.nejm.org at UNIVERSITY HOSPITALS OF CLEVELAND on May 26, 2006 .
Copyright © 1997 Massachusetts Medical Society. All rights reserved.

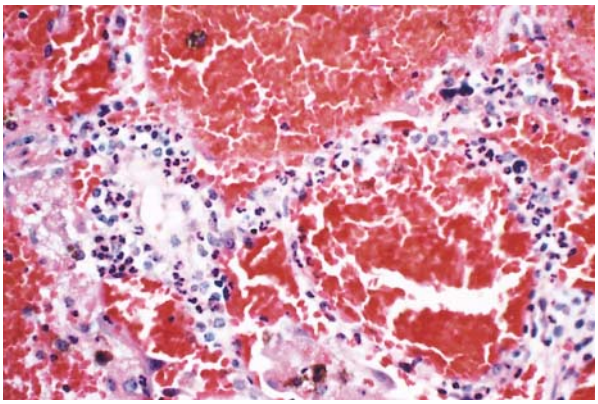

Figure 5. Pulmonary Hemorrhagic Alveolar Capillaritis in a Patient with ANCA-Associated Small-Vessel Vasculitis in Whom Severe Hemoptysis Developed.

There are numerous neutrophils in the alveolar septa and extensive hemorrhage into the alveolar spaces. (Hematoxylin and eosin, ×400.)

cavitating radiographic densities. The acute inflammatory and necrotizing pulmonary lesions evolve into chronic nonspecific sclerotic lesions, such as interstitial fibrosis, organized intraalveolar fibrosis, and bronchiolitis obliterans.[70]

Diagnostic Strategy

There are no agreed-upon diagnostic criteria for the various categories of small-vessel vasculitis. In 1990 the American College of Rheumatology published an approach to classifying vasculitides for clinical trials.[71] These criteria were not designed for diagnosis, although they are being widely used for this purpose. They are not adequate for differentiating among the various clinicopathological expressions of small-vessel vasculitis. For example, a 20-year-old patient with small-vessel vasculitis who has purpura, leukocytoclastic angiitis, myalgias, mononeuritis multiplex, and nephritis would simultaneously fulfill the College's criteria for three different categories of vasculitis: hypersensitivity vasculitis, Henoch–Schönlein purpura, and polyarteritis nodosa. The system does not have a category called "microscopic polyangiitis" or "microscopic polyarteritis"; thus, most cases of ANCA-positive microscopic polyangiitis would be called hypersensitivity angiitis, according to the College's system.

In 1994 the Chapel Hill International Consensus Conference proposed names and definitions for selected categories of vasculitis[1]; however, no diagnostic criteria were suggested.

The following discussion presents a number of observations that can be made to help determine which definition of vasculitis is met in a given patient, and thus the diagnosis. This requires the knowledgeable integration of clinical and laboratory data, both positive and negative. Laboratory assessment for ANCA, antinuclear antibodies, complement, cryoglobulins, fecal blood, antibodies to hepatitis B and C, rheumatoid factor, azotemia, hematuria, and proteinuria is useful. Chest and sinus radiographs and computed tomographic scans may reveal occult respiratory tract disease. Nerve-conduction studies can document peripheral neuropathy. Evidence of conditions that are known to cause vasculitis, such as drug hypersensitivity, infection, rheumatoid arthritis, systemic lupus erythematosus, cancer, and inflammatory bowel disease, should be sought. Pathological examination of involved tissue, such as skin, muscle, nerve, lung, or kidney, may document small-vessel vasculitis. Immunohistologic evaluation may yield more specific information, such as the presence of IgA-dominant vascular immune deposits indicative of Henoch–Schönlein purpura, or IgM and IgG immune complexes that are consistent with cryoglobulinemic vasculitis.

Cutaneous Leukocytoclastic Angiitis

Small-vessel vasculitis may be confined to the skin. The characteristic acute lesion is leukocytoclastic angiitis involving dermal postcapillary venules (Fig. 4). This lesion is histologically identical to dermal lesions occurring as a component of systemic small-vessel vasculitis.[66] Therefore, the onus is on the physician to rule out systemic disease.

Drug-induced vasculitis should be considered in any patient with small-vessel vasculitis and will be substantiated most often in patients with vasculitis confined to the skin. Drugs cause approximately 10 percent of vasculitic skin lesions.[72,73] Drug-induced vasculitis usually develops within 7 to 21 days after treatment begins.

Drugs that have been implicated include penicillins, aminopenicillins, sulfonamides, allopurinol, thiazides, pyrazolones, retinoids, quinolones, hydantoins, and propylthiouracil.[74] Some drugs, such as penicillins, cause vasculitis by conjugating to serum proteins and mediating immune-complex vasculitis that is similar to serum-sickness vasculitis.[75] Other vasculitis-inducing drugs that cause immune-complex formation are foreign proteins, such as streptokinase, cytokines, and monoclonal antibodies.[76] In addition, such drugs as propylthiouracil and hydralazine appear to cause vasculitis by inducing ANCA,[77-80] although a cause-and-effect relation has not been proved.

Most patients with cutaneous leukocytoclastic angiitis have a single episode that resolves spontaneously within several weeks or a few months.[81] Approximately 10 percent will have recurrent disease at intervals of months to years. In the absence of systemic disease, management is usually symptomatic. Drugs that could cause the disease should be stopped. Antihistamines and nonsteroidal antiinflammatory drugs

Downloaded from www.nejm.org at UNIVERSITY HOSPITALS OF CLEVELAND on May 26, 2006 .
Copyright © 1997 Massachusetts Medical Society. All rights reserved.

help alleviate cutaneous discomfort and reduce associated arthralgias and myalgias.[81] Severe cutaneous disease may warrant oral corticosteroid therapy.[81] If signs or symptoms of systemic vasculitis develop, treatment should be based on the type of systemic vasculitis the patient has.

Henoch–Schönlein Purpura

Henoch–Schönlein purpura is the most common systemic vasculitis in children.[82] It is characterized by vascular deposition of IgA-dominant immune complexes,[1,33] and preferentially involves venules, capillaries, and arterioles (Fig. 1).

Henoch–Schönlein purpura is most frequent in childhood, with a peak incidence at five years old.[49,50,82] The disease often begins after an upper respiratory tract infection. Purpura, arthralgias, and colicky abdominal pain are the most frequent manifestations (Table 4). Approximately half the patients have hematuria and proteinuria, but only 10 to 20 percent have renal insufficiency. Rapidly progressive renal failure is rare. Pulmonary disease and peripheral neuropathy are uncommon.[83,84]

The overall prognosis is excellent; thus, supportive care suffices for most patients. The main long-term morbidity is from progressive renal disease. End-stage renal disease develops in approximately 5 percent of patients.[51] Treatment for aggressive Henoch–Schönlein purpura glomerulonephritis is controversial. Corticosteroids, immunosuppressive drugs, and anticoagulant therapy have been tried with contradictory results, but a recent study suggests that combined therapy with corticosteroids and azathioprine may be beneficial.[85]

Although the term "Henoch–Schönlein purpura" was originally used to designate a syndrome that can be characterized by many different types of small-vessel vasculitis (i.e., combinations of purpura, abdominal pain, and nephritis), the use of the term should now be restricted to the specific clinicopathological entity caused by vascular IgA-dominant immune complexes.[1] The misuse of this term for patients with ANCA-associated small-vessel vasculitis who present with purpura, abdominal pain, and nephritis is particularly problematic, because these patients do not have a good prognosis and should be treated quickly with immunosuppressive therapy, as will be discussed later in this review.

Cryoglobulinemic Vasculitis

Cryoglobulinemic vasculitis is caused by the localization of mixed cryoglobulins in vessel walls, which incites acute inflammation. Venules, capillaries, and arterioles are preferentially involved (Fig. 1).

Patients with this disease have an average age of approximately 50 years. The most frequent manifestations are purpura, arthralgias, and nephritis (Table 4).[52] Mixed cryoglobulins and rheumatoid-factor activity are typically detectable in serum. Most patients have an associated infection with hepatitis C virus, which is thought to be etiologic.[53,86,87] A very distinctive and diagnostically useful complement abnormality is the presence of very low levels of early components (especially C4) with normal or slightly low C3 levels.[53,87] As with Henoch–Schönlein purpura, the main cause of morbidity is progressive glomerulonephritis, which most often has a type I membranoproliferative phenotype.

Mild disease, such as slight purpura and arthralgias, usually is adequately treated with nonsteroidal antiinflammatory drugs alone. Serious visceral involvement, such as in glomerulonephritis, usually requires treatment with corticosteroids combined with a cytotoxic drug (e.g., cyclophosphamide), which improves the outcome of glomerulonephritis and also ameliorates purpura, arthralgias, and other vasculitic symptoms.[53,87] Plasmapheresis has been used, but its value is unproved. Recently, interferon alfa has been touted as a beneficial adjuvant in patients with cryoglobulinemic vasculitis associated with hepatitis C virus infection,[53,87] but larger controlled trials are required before the value of this approach can be conclusively determined.

ANCA-Associated Small-Vessel Vasculitis

ANCA-associated small-vessel vasculitis is the most common primary systemic small-vessel vasculitis in adults and includes three major categories: Wegener's granulomatosis, microscopic polyangiitis, and Churg–Strauss syndrome. These histologically identical small-vessel vasculitides preferentially involve venules, capillaries, and arterioles, and may also involve arteries and veins (Fig. 1).[88] Wegener's granulomatosis is differentiated from the other two by the presence of necrotizing granulomatous inflammation in the absence of asthma; Churg–Strauss syndrome is differentiated by the presence of asthma, eosinophilia, and necrotizing granulomatous inflammation; and microscopic polyangiitis is differentiated by the absence of granulomatous inflammation and asthma[1] (Tables 2 and 3). Rapid diagnosis of ANCA-associated small-vessel vasculitis is critically important, because life-threatening injury to organs often develops quickly and is mitigated dramatically by immunosuppressive treatment.

ANCA-associated small-vessel vasculitis affects people of all ages but is most common in older adults in their 50s and 60s, and it affects men and women equally.[54,89] In the United States the disease is more frequent among whites than blacks.[89] Its incidence is approximately 2 in 100,000 people in the United Kingdom[90] and approximately 1 in 100,000 in Sweden.[54] Although Wegener's granulomatosis, microscopic polyangiitis, and Churg–Strauss syndrome are categorized as ANCA-associated small-vessel vasculitis, it is important to realize that a minority of pa-

Downloaded from www.nejm.org at UNIVERSITY HOSPITALS OF CLEVELAND on May 26, 2006 .
Copyright © 1997 Massachusetts Medical Society. All rights reserved.

tients with typical clinical and pathological features of these diseases are ANCA-negative.

Wegener's granulomatosis. Over 90 percent of patients with Wegener's granulomatosis have upper or lower respiratory tract disease or both.[55-57] Manifestations of upper respiratory tract disease include sinus pain, purulent sinus drainage, nasal mucosal ulceration with epistaxis, and otitis media. More serious complications include necrosis of the nasal septum with perforation or saddle-nose deformation and injury to the facial nerve by otitis media resulting in facial paralysis. Tracheal inflammation and sclerosis, often in the subglottic region, cause stridor and may lead to dangerous airway stenosis, which occurs in approximately 15 percent of adults and almost 50 percent of children with this disease.[57] A minority of patients initially have indolent or aggressive upper respiratory tract disease alone, but most also have pulmonary disease.

Necrotizing granulomatous pulmonary inflammation produces nodular radiographic densities, whereas alveolar capillaritis causes pulmonary hemorrhage with less fixed and more irregular infiltrates. Massive pulmonary hemorrhage caused by capillaritis is the most life-threatening manifestation of ANCA-associated small-vessel vasculitis and warrants rapid institution of aggressive immunosuppressive therapy.

Approximately 80 percent of patients with Wegener's granulomatosis will go on to have glomerulonephritis, although less than 20 percent have nephritis at the time of presentation.[57] The glomerulonephritis is characterized by focal necrosis, crescent formation, and the absence or paucity of immunoglobulin deposits.[35,88] An identical pauci-immune necrotizing and crescentic glomerulonephritis occurs in patients with microscopic polyangiitis and Churg–Strauss syndrome, and also occurs as a disease limited to the kidneys. Other manifestations of the disease include ocular inflammation, cutaneous purpura and nodules, peripheral neuropathy, arthritis, and diverse abdominal visceral involvement (Table 4).[55-57]

The classic triad of respiratory tract granulomatous inflammation, systemic small-vessel vasculitis, and necrotizing glomerulonephritis[7] readily suggests the diagnosis, but atypical presentations, such as isolated subglottic stenosis or orbital pseudotumor, may not. In patients with the latter presentation, a positive ANCA test is helpful for substantiating a diagnosis of Wegener's granulomatosis.[91,92]

Treatment of aggressive Wegener's granulomatosis, as well as of microscopic polyangiitis, has three phases: induction of remission, maintenance of remission, and treatment of relapse.[93] After the seminal observations of Novack and Pearson,[94] Fauci and his associates documented the value of cyclophosphamide in the treatment of Wegener's granulomatosis.[55] Current induction therapy often uses cyclophosphamide combined with corticosteroids. Corticosteroids alone may be adequate for ameliorating indolent limited disease but are inadequate for patients with generalized disease.[57] In patients with Wegener's granulomatosis or microscopic polyangiitis who have aggressive disease, such as acute nephritis or pulmonary hemorrhage, we recommend induction with intravenous methylprednisolone at a dose of 7 mg per kilogram of body weight per day for three days, followed by tapering doses of prednisone. This treatment is combined with oral cyclophosphamide at 2 mg per kilogram per day, or intravenous cyclophosphamide at 0.5 g per square meter of body-surface area per month, adjusted upward to 1 g per square meter on the basis of the patient's leukocyte count.[58] Combined therapy with corticosteroids and cyclophosphamide induces improvement in over 90 percent of patients with Wegener's granulomatosis and complete remission in 75 percent.[59] A common strategy is to discontinue corticosteroids after remission is achieved, usually within 3 to 5 months, and to continue cyclophosphamide for 6 to 12 months. An alternative strategy for maintaining remission is conversion from cyclophosphamide to azathioprine once remission is achieved.[90] Approximately 50 percent of patients with Wegener's granulomatosis have at least one relapse within five years.[59] The best treatment for reversing relapses is controversial but usually involves reinstituting treatment similar to the induction regimen.[57]

Both corticosteroids and cyclophosphamide predispose patients to life-threatening infections, and cyclophosphamide causes hemorrhagic cystitis, ovarian and testicular failure, and cancer. For example, Talar-Williams et al. have estimated the incidence of bladder cancer after the first exposure to cyclophosphamide to be 5 percent 10 years after treatment and 16 percent after 15 years.[95] The risks and benefits of aggressive immunosuppression must be assessed in each patient, and the treatment tailored accordingly. There should be vigilance for and prompt treatment of complications arising from treatment.

Less-toxic therapy may be sufficient in patients with localized or mild Wegener's granulomatosis. For example, Sneller et al. achieved remission with low-dose methotrexate plus prednisone in 71 percent of patients with Wegener's granulomatosis that was "not immediately life-threatening."[96] Methotrexate also may be useful for maintenance of remission.[97] Treatment with methotrexate is limited in patients with renal disease because of increased toxicity.

Because relapses are associated with respiratory tract infections and with chronic nasal carriage of *Staphylococcus aureus*,[98] the antimicrobial agent trimethoprim–sulfamethoxazole has been evaluated for maintenance of remission, with mixed results. Stegeman et al.[99] concluded that it is useful for maintaining remission, but de Groot et al. did not agree.[97]

Microscopic polyangiitis. Microscopic polyangiitis

Downloaded from www.nejm.org at UNIVERSITY HOSPITALS OF CLEVELAND on May 26, 2006 .
Copyright © 1997 Massachusetts Medical Society. All rights reserved.

is characterized by pauci-immune necrotizing small-vessel vasculitis without clinical or pathological evidence of necrotizing granulomatous inflammation (Tables 2 and 3).[1] Over 80 percent of patients with microscopic polyangiitis have ANCA, most often perinuclear ANCA (MPO-ANCA).[40-42,54] This helps distinguish microscopic polyangiitis from ANCA-negative small-vessel vasculitis but does not distinguish microscopic polyangiitis from other types of disease associated with ANCA. Positive ANCA and negative serologic tests for hepatitis B help differentiate microscopic polyangiitis from polyarteritis nodosa.[60]

Pathologically, microscopic polyangiitis may cause necrotizing arteritis that is histologically identical to that caused by polyarteritis nodosa. By the approach advocated by the Chapel Hill Consensus Conference (Table 2),[1] polyarteritis nodosa and microscopic polyangiitis are distinguished pathologically by the absence of vasculitis in vessels other than arteries in polyarteritis nodosa and the presence of vasculitis in vessels smaller than arteries (i.e., arterioles, venules, and capillaries) in microscopic polyangiitis. According to this definition, the presence of dermal leukocytoclastic venulitis, glomerulonephritis, pulmonary alveolar capillaritis, or vasculitis in any vessel smaller than an artery would exclude a diagnosis of polyarteritis nodosa and indicate some form of small-vessel vasculitis. On the other hand, identification of necrotizing arteritis in a skeletal-muscle biopsy or peripheral-nerve biopsy, for example, indicates some form of necrotizing vasculitis but is not diagnostic of polyarteritis nodosa, because many other necrotizing vasculitides, such as microscopic polyangiitis, Wegener's granulomatosis, and Churg–Strauss syndrome, can also affect arteries (Fig. 1).

Microscopic polyangiitis has the same spectrum of manifestations of small-vessel vasculitis as Wegener's granulomatosis but does not include granulomatous inflammation.[54,58,61,62] Approximately 90 percent of patients have glomerulonephritis, which is accompanied by a variety of other organ involvements (Table 4). Microscopic polyangiitis is the most common cause of the pulmonary–renal syndrome.[22]

Microscopic polyangiitis that is causing major organ damage is treated with a combination of corticosteroids and cytotoxic agents. Our treatment approach is the same as that for aggressive Wegener's granulomatosis, which was described earlier in this review, and uses intravenous methylprednisolone followed by prednisone combined with intravenous or oral cyclophosphamide.[58] Alveolar capillaritis (Fig. 5) with pulmonary hemorrhage is the most life-threatening complication and should be treated promptly with combined therapy,[58,61] and possibly with plasmapheresis.[61] The glomerulonephritis is usually rapidly progressive if not promptly and appropriately treated with a combination of high-dose corticosteroids and cyclophosphamide, which induces remission in approximately 80 percent of patients.[58,61] The greatest risk factor for a poor renal outcome is a delay in treatment until renal insufficiency has developed.[63] Relapse occurs in about a third of patients within two years.[54,58,61] Approximately two thirds of patients who relapse respond to an immunosuppressive regimen similar to the induction therapy.

Because the treatment of microscopic polyangiitis and Wegener's granulomatosis is essentially the same when there is major organ injury, it is not necessary to distinguish conclusively between these closely related variants of ANCA-associated small-vessel vasculitis before starting treatment. For example, an ANCA-positive patient with pulmonary infiltrates, hemoptysis, and pauci-immune crescentic glomerulonephritis on renal biopsy may have either microscopic polyangiitis or Wegener's granulomatosis. Resolving this differential diagnosis should not delay the start of induction therapy with combined corticosteroids and cyclophosphamide.

Churg–Strauss syndrome. Churg–Strauss syndrome has three phases: allergic rhinitis and asthma; eosinophilic infiltrative disease, such as eosinophilic pneumonia or gastroenteritis; and systemic small-vessel vasculitis with granulomatous inflammation.[62,64,65] The vasculitic phase usually develops within three years of the onset of asthma, although it may be delayed for several decades. Approximately 70 percent of patients with this disease have ANCA, usually perinuclear ANCA (MPO-ANCA).[62] Virtually all patients have eosinophilia (more than 10 percent eosinophils in the blood).[65]

As compared with Wegener's granulomatosis and microscopic polyangiitis, Churg–Strauss syndrome involves much less frequent and less severe renal disease, but more frequent neuropathy and cardiac disease.[62,65] Coronary arteritis and myocarditis are the principal causes of morbidity and mortality, accounting for approximately 50 percent of deaths, and can be reduced by early treatment.

High-dose corticosteroid treatment alone is often adequate, although refractory or relapsing disease may require the addition of a cytotoxic drug — for example, in a regimen similar to that used for Wegener's granulomatosis or microscopic polyangiitis.[62,64]

RECOMMENDATIONS

Treatment of a patient with small-vessel vasculitis should include these steps: recognition that small-vessel vasculitis is present, determination of as specific a diagnosis as possible, determination of the prognosis, and initiation of therapy or referral to an appropriate specialist. In many patients, small-vessel vasculitis will have a relatively benign, self-limited course, especially if disease is limited to the skin; however, for the patients with aggressive disease, such as generalized ANCA-associated small-vessel

Downloaded from www.nejm.org at UNIVERSITY HOSPITALS OF CLEVELAND on May 26, 2006 .
Copyright © 1997 Massachusetts Medical Society. All rights reserved.

vasculitis, it is imperative to begin appropriate treatment quickly. The goal should be neither to overtreat mild disease nor to undertreat severe disease.

We are indebted to the other members of the Chapel Hill Consensus Conference on the Nomenclature of Systemic Vasculitis for their contributions to our understanding of vasculitis: K. Andrassy, P.A. Bacon, J. Churg, W.L. Gross, E.C. Hagen, G.S. Hoffman, G.G. Hunder, C.G.M. Kallenberg, R.T. McCluskey, R.A. Sinico, A.J. Rees, L.A. van Es, R. Waldherr, and A. Wiik.

REFERENCES

1. Jennette JC, Falk RJ, Andrassy K, et al. Nomenclature of systemic vasculitides: proposal of an international consensus conference. Arthritis Rheum 1994;37:187-92.
2. Kussmaul A, Maier R. Ueber eine bisher nicht beschreibene eigenthümliche Arterienerkrankung (Periarteriitis nodosa), die mit Morbus Brightii und rapid fortschreitender allgemeiner Muskellähmung einhergeht. Dtsch Arch Klin Med 1866;1:484-518.
3. Arkin A. A clinical and pathological study of periarteritis nodosa: a report of five cases, one histologically healed. Am J Pathol 1930;6:401-26.
4. Davson J, Ball J, Platt R. The kidney in periarteritis nodosa. QJM 1948; 17:175-202.
5. Zeek PM, Smith CC, Weeter JC. Studies on periarteritis nodosa. III. The differentiation between the vascular lesions of periarteritis nodosa and of hypersensitivity. Am J Pathol 1948;24:889-917.
6. Zeek PM. Periarteritis nodosa: a critical review. Am J Clin Pathol 1952; 22:777-90.
7. Godman GC, Churg J. Wegener's granulomatosis: pathology and review of the literature. Arch Pathol 1954;58:533-53.
8. Klinger H. Grenzformen der Periarteriitis nodosa. Frankf Z Pathol 1931;42:455-80.
9. Wegener F. Über eine eigenartige rhinogene Granulomatose mit besonderer Beteilgung des Arteriensystems und den Nieren. Beitr Pathol Anat Allg Pathol 1939;102:36-68.
10. Carrington CB, Liebow AA. Limited forms of angiitis and granulomatosis of Wegener's type. Am J Med 1966;41:497-527.
11. Churg J, Strauss L. Allergic granulomatosis, allergic angiitis, and periarteritis nodosa. Am J Pathol 1951;27:277-94.
12. Alarcón-Segovia D. Classification of the necrotizing vasculitides in man. Clin Rheum Dis 1980;6:223-31.
13. Purpura. In: Willan R. On cutaneous diseases. Vol. 1. Philadelphia: Kimber & Conrad, 1808:452-71.
14. Schönlein JL. Allgemeine und specielle Pathologie und Therapie. 3rd ed. Vol. 2. Herisau, Switzerland: Literatur-Comptoir, 1837:48.
15. Henoch E. Über den Zusammenhang von Purpura und Intestinal störungen. Berl Klin Wochenschr 1868;5:517-9.
16. Henoch EH. Lectures on diseases of children: a handbook for physicians and students. New York: W. Wood, 1882.
17. Osler W. On the visceral complications of erythema exudativum multiforme. Am J Med Sci 1895;110:629-46.
18. *Idem.* The visceral lesions of purpura and allied conditions. BMJ 1914; 1:517-25.
19. Goodpasture EW. The significance of certain pulmonary lesions in relation to the etiology of influenza. Am J Med Sci 1919;158:863-70.
20. Martinez JS, Kohler PF. Variant "Goodpasture's syndrome"? The need for immunologic criteria in rapidly progressive glomerulonephritis and hemorrhagic pneumonitis. Ann Intern Med 1971;75:67-76.
21. Leatherman JW, Sibley RK, Davies SF. Diffuse intrapulmonary hemorrhage and glomerulonephritis unrelated to anti-glomerular basement membrane antibody. Am J Med 1982;72:401-10.
22. Niles JL, Bottinger EP, Saurina GR, et al. The syndrome of lung hemorrhage and nephritis is usually an ANCA-associated condition. Arch Intern Med 1996;156:440-5.
23. Jones DA, Jennette JC, Falk RJ. Goodpasture's syndrome revisited: a new perspective on glomerulonephritis and alveolar hemorrhage. N C Med J 1990;51:411-5.
24. Storck H. Über hämorrhagische Phänomene in der Dermatologie. Dermatologica 1951;102:197-252.
25. Winklemann RK. Clinical and pathologic findings in the skin in anaphylactoid purpura (allergic angiitis). Mayo Clin Proc 1958;33:277-88.
26. Clark E, Kaplan BI. Endocardial, arterial and other mesenchymal alterations associated with serum disease in man. Arch Pathol 1937;24:458-75.
27. Winkelmann RK, Ditto WB. Cutaneous and visceral syndromes of necrotizing or "allergic" angiitis: a study of 38 cases. Medicine (Baltimore) 1964;43:59-89.
28. Alarcón-Segovia D, Brown AL Jr. Classification and etiologic aspects of necrotizing angiitides: an analytic approach to a confused subject with a critical review of the evidence for hypersensitivity in polyarteritis nodosa. Mayo Clin Proc 1964;39:205-22.
29. Scheer RL, Grossman MA. Immune aspects of the glomerulonephritis associated with pulmonary hemorrhage. Ann Intern Med 1964;60:1009-21.
30. Sturgill BC, Westervelt FB. Immunofluorescence studies in a case of Goodpasture's syndrome. JAMA 1965;194:914-6.
31. Lerner RA, Glassock RJ, Dixon FJ. The role of anti-glomerular basement membrane antibody in the pathogenesis of human glomerulonephritis. J Exp Med 1967;126:989-1004.
32. Meltzer M, Franklin EC, Elias K, McCluskey RT, Cooper N. Cryoglobulinemia — a clinical and laboratory study. II. Cryoglobulins with rheumatoid factor activity. Am J Med 1966;40:837-56.
33. Faille-Kuyber EH, Kater L, Kooiker CJ, Dorhout Mees EJ. IgA-deposits in cutaneous blood-vessel walls and mesangium in Henoch-Schönlein syndrome. Lancet 1973;1:892-3.
34. Gower RG, Sausker WF, Kohler PF, Thorne GE, McIntosh RM. Small vessel vasculitis caused by hepatitis B virus immune complexes: small vessel vasculitis and HBsAG. J Allergy Clin Immunol 1978;62:222-8.
35. Ronco P, Verroust P, Mignon F, et al. Immunopathological studies of polyarteritis nodosa and Wegener's granulomatosis: a report of 43 patients with 51 renal biopsies. QJM 1983;52:212-23.
36. Weiss MA, Crissman JD. Renal biopsy findings in Wegener's granulomatosis: segmental necrotizing glomerulonephritis with glomerular thrombosis. Hum Pathol 1984;15:943-56.
37. Davies DJ, Moran JE, Niall JF, Ryan GB. Segmental necrotising glomerulonephritis with antineutrophil antibody: possible arbovirus aetiology? BMJ 1982;285:606.
38. Hall JB, Wadham BM, Wood CJ, Ashton V, Adam WR. Vasculitis and glomerulonephritis: a subgroup with an antineutrophil cytoplasmic antibody. Aust N Z J Med 1984;14:277-8.
39. van der Woude FJ, Rasmussen N, Lobatto S, et al. Autoantibodies against neutrophils and monocytes: tool for diagnosis and marker of disease activity in Wegener's granulomatosis. Lancet 1985;1:425-9.
40. Gross WL, Schmitt WH, Csernok E. ANCA and associated diseases: immunodiagnostic and pathogenetic aspects. Clin Exp Immunol 1993;91: 1-12.
41. Kallenberg CGM, Brouwer E, Weening JJ, Cohen Tervaert JW. Antineutrophil cytoplasmic antibodies: current diagnostic and pathophysiologic potential. Kidney Int 1994;46:1-15.
42. Jennette JC, Falk RJ. Anti-neutrophil cytoplasmic autoantibodies: discovery, specificity, disease associations and pathogenic potential. Adv Pathol Lab Med 1995;8:363-78.
43. Falk RJ, Jennette JC. Anti-neutrophil cytoplasmic autoantibodies with specificity for myeloperoxidase in patients with systemic vasculitis and idiopathic necrotizing and crescentic glomerulonephritis. N Engl J Med 1988;318:1651-7.
44. Goldschmeding R, van der Schoot CE, ten Bokkel Huinink D, et al. Wegener's granulomatosis autoantibodies identify a novel diisopropylfluorophosphate-binding protein in the lysosomes of normal human neutrophils. J Clin Invest 1989;84:1577-87.
45. Niles JL, McCluskey RT, Ahmad MF, Arnaout MA. Wegener's granulomatosis autoantigen is a novel neutrophil serine proteinase. Blood 1989; 74:1888-93.
46. Ludemann J, Utecht B, Gross WL. Anti-neutrophil cytoplasm antibodies in Wegener's granulomatosis recognize an elastinolytic enzyme. J Exp Med 1990;171:357-62.
47. Jennette JC, Hoidal JR, Falk RJ. Specificity of anti-neutrophil cytoplasmic autoantibodies for proteinase 3. Blood 1990;75:2263-4.
48. Merkel PA, Polisson RP, Chang YC, Skates SJ, Niles JL. Prevalence of antineutrophil cytoplasmic antibodies in a large inception cohort of patients with connective tissue disease. Ann Intern Med 1997;126:866-73.
49. Mills JA, Michel BA, Bloch DA, et al. The American College of Rheumatology 1990 criteria for the classification of Henoch-Schönlein purpura. Arthritis Rheum 1990;33:1114-21.
50. Michel BA, Hunder GG, Bloch DA, Calabrese LH. Hypersensitivity vasculitis and Henoch-Schönlein purpura: a comparison between the 2 disorders. J Rheumatol 1992;19:721-8.
51. Goldstein AR, White RHR, Akuse R, Chantler C. Long-term follow-up of childhood Henoch-Schönlein nephritis. Lancet 1992;339:280-2.
52. Gorevic PD, Kassab HJ, Levo Y, et al. Mixed cryoglobulinemia: clinical aspects and long-term follow-up of 40 patients. Am J Med 1980;69:287-308.
53. Agnello V, Romain PL. Mixed cryoglobulinemia secondary to hepatitis C virus infection. Rheum Dis Clin North Am 1996;22:1-21.
54. Pettersson EE, Sundelin B, Heigl Z. Incidence and outcome of pauci-

Downloaded from www.nejm.org at UNIVERSITY HOSPITALS OF CLEVELAND on May 26, 2006 .
Copyright © 1997 Massachusetts Medical Society. All rights reserved.

immune necrotizing and crescentic glomerulonephritis in adults. Clin Nephrol 1995;43:141-9.
55. Fauci AS, Haynes BF, Katz P, Wolff SM. Wegener's granulomatosis: prospective clinical and therapeutic experience with 85 patients for 21 years. Ann Intern Med 1983;98:76-85.
56. Leavitt RY, Fauci AS, Bloch DA, et al. The American College of Rheumatology 1990 criteria for the classification of Wegener's granulomatosis. Arthritis Rheum 1990;33:1101-7.
57. Duna GF, Galperin C, Hoffman GS. Wegener's granulomatosis. Rheum Dis Clin North Am 1995;21:949-86.
58. Nachman PH, Hogan SL, Jennette JC, Falk RJ. Treatment response and relapse in antineutrophil cytoplasmic autoantibody-associated microscopic polyangiitis and glomerulonephritis. J Am Soc Nephrol 1996;7:33-9.
59. Hoffman GS, Kerr GS, Leavitt RY, et al. Wegener's granulomatosis: an analysis of 158 patients. Ann Intern Med 1992;116:488-98.
60. Guillevin L, Lhote F, Amouroux J, Gherardi R, Callard P, Casassus P. Antineutrophil cytoplasmic antibodies, abnormal angiograms and pathological findings in polyarteritis nodosa and Churg-Strauss syndrome: indications for the classification of vasculitides of the polyarteritis nodosa group. Br J Rheumatol 1996;35:958-64.
61. Savage COS, Winearls CG, Evans DJ, Rees AJ, Lockwood CM. Microscopic polyarteritis: presentation, pathology and prognosis. QJM 1985; 220:467-83.
62. Lhote F, Guillevin L. Polyarteritis nodosa, microscopic polyangiitis, and Churg-Strauss syndrome: clinical aspects and treatment. Rheum Dis Clin North Am 1995;21:911-47.
63. Hogan SL, Nachman PH, Wilkman AS, Jennette JC, Falk RJ, Glomerular Disease Collaborative Network. Prognostic markers in patients with antineutrophil cytoplasmic autoantibody-associated microscopic polyangiitis and glomerulonephritis. J Am Soc Nephrol 1996;7:23-32.
64. Lanham JG, Elkon KB, Pusey CD, Hughes GR. Systemic vasculitis with asthma and eosinophilia: a clinical approach to the Churg-Strauss syndrome. Medicine (Baltimore) 1984;63:65-81.
65. Masi AT, Hunder GG, Lie JT, et al. The American College of Rheumatology 1990 criteria for the classification of Churg-Strauss syndrome (allergic granulomatosis and angiitis). Arthritis Rheum 1990;33:1094-100.
66. Jennette JC, Milling DM, Falk RJ. Vasculitis affecting the skin: a review. Arch Dermatol 1994;130:899-906.
67. Mehregan DR, Hall MJ, Gibson LE. Urticarial vasculitis: a histopathologic and clinical review of 72 cases. J Am Acad Dermatol 1992;26:441-8.
68. Panegyres PK, Blumbergs PC, Leong AS, Bourne AJ. Vasculitis of peripheral nerve and skeletal muscle: clinicopathological correlation and immunopathic mechanisms. J Neurol Sci 1990;100:193-202.
69. Kissel JT, Mendell JR. Vasculitic neuropathy. Neurol Clin 1992;10: 761-81.
70. Gaudin PB, Askin FB, Falk RJ, Jennette JC. The pathologic spectrum of pulmonary lesions in patients with anti-neutrophil cytoplasmic autoantibodies specific for anti-proteinase 3 and anti-myeloperoxidase. Am J Clin Pathol 1995;104:7-16.
71. Hunder GG, Arend WP, Bloch DA, et al. The American College of Rheumatology 1990 criteria for the classification of vasculitis: introduction. Arthritis Rheum 1990;33:1065-7.
72. Ekenstam E, Callen JP. Cutaneous leukocytoclastic vasculitis: clinical and laboratory features of 82 patients seen in private practice. Arch Dermatol 1984;120:484-9.
73. Sanchez NP, Van Hale HM, Su WPD. Clinical and histopathologic spectrum of necrotizing vasculitis: report of findings in 101 cases. Arch Dermatol 1985;121:220-4.
74. Wolkenstein P, Revuz J. Drug-induced severe skin reactions: incidence, management and prevention. Drug Saf 1995;13:56-68.
75. Parker CW. Drug allergy. N Engl J Med 1975;292:511-4.
76. Lantin JP, Gattesco S, Duclos A, et al. Anaphylactoid purpura like vasculitis following fibrinolytic therapy: role of the immune response to streptokinase. Clin Exp Rheumatol 1994;12:429-33.
77. Tanemoto M, Miyakawa H, Hanai J, Yago M, Kitaoka M, Uchida S. Myeloperoxidase-antineutrophil cytoplasmic antibody-positive crescentic glomerulonephritis complicating the course of Graves' disease: report of three adult cases. Am J Kidney Dis 1995;26:774-80.
78. Dolman KM, Gans ROB, Vervaat TJ, et al. Vasculitis and antineutrophil cytoplasmic autoantibodies associated with propylthiouracil therapy. Lancet 1993;342:651-2.
79. Short AK, Lockwood CM. Antigen specificity of hydralazine associated ANCA positive systemic vasculitis. QJM 1995;88:775-83.
80. D'Cruz D, Chesser AM, Lightowler C, et al. Antineutrophil cytoplasmic antibody-positive crescentic glomerulonephritis associated with antithyroid drug treatment. Br J Rheumatol 1995;34:1090-1.
81. Swerlick RA, Lawley TJ. Cutaneous vasculitis: its relationship to systemic disease. Med Clin North Am 1989;73:1221-35.
82. Dillon MJ, Ansell BM. Vasculitis in children and adolescents. Rheum Dis Clin North Am 1995;21:1115-36.
83. Wright WK, Krous HF, Griswold WR, et al. Pulmonary vasculitis with hemorrhage in anaphylactoid purpura. Pediatr Pulmonol 1994;17:269-71.
84. Belman AL, Leicher CR, Moshe SL, Mezey AP. Neurologic manifestations of Schoenlein-Henoch purpura: report of three cases and review of the literature. Pediatrics 1985;75:687-92.
85. Bergstein J, Leiser J, Andreoli S. Response of crescentic Henoch-Schoenlein purpura nephritis (HSP GN) to corticosteroid and azathioprine (AZA) therapy. J Am Soc Nephrol 1996;7:1328-9. abstract.
86. Agnello V, Chung RT, Kaplan LM. A role for hepatitis C virus infection in type II cryoglobulinemia. N Engl J Med 1992;327:1490-5.
87. D'Amico G, Fornasieri A. Cryoglobulinemic glomerulonephritis: a membranoproliferative glomerulonephritis induced by hepatitis C virus. Am J Kidney Dis 1995;25:361-9.
88. Jennette JC. Antineutrophil cytoplasmic autoantibody-associated diseases: a pathologist's perspective. Am J Kidney Dis 1991;18:164-70.
89. Falk RJ, Hogan S, Carey TS, Jennette JC. The clinical course of antineutrophil cytoplasmic autoantibody-associated glomerulonephritis and systemic vasculitis. Ann Intern Med 1990;113:656-63.
90. Savage COS, Harper L, Adu D. Primary systemic vasculitis. Lancet 1997;349:553-8.
91. Gaughan RK, DeSanto LW, McDonald TJ. Use of anticytoplasmic autoantibodies in the diagnosis of Wegener's granulomatosis with subglottic stenosis. Laryngoscope 1990;100:561-3.
92. Yamashita K, Kobayashi K, Kondo M, Ishikura H, Shibuya Y, Hayasaka S. Elevated anti-neutrophil cytoplasmic antibody titer in a patient with atypical orbital pseudotumor. Ophthalmologica 1995;209:172-5.
93. Bacon PA. Therapy of vasculitis. J Rheumatol 1994;21:788-90.
94. Novack SN, Pearson CM. Cyclophosphamide therapy in Wegener's granulomatosis. N Engl J Med 1971;284:938-42.
95. Talar-Williams C, Hijazi YM, Walther MM, et al. Cyclophosphamide-induced cystitis and bladder cancer in patients with Wegener granulomatosis. Ann Intern Med 1996;124:477-84.
96. Sneller MC, Hoffman GS, Talar-Williams C, Kerr GS, Hallahan CW, Fauci AS. An analysis of forty-two Wegener's granulomatosis patients treated with methotrexate and prednisone. Arthritis Rheum 1995;38:608-13.
97. de Groot K, Reinhold-Keller E, Tatsis E, et al. Therapy for the maintenance of remission in sixty-five patients with generalized Wegener's granulomatosis: methotrexate versus trimethoprim/sulfamethoxazole. Arthritis Rheum 1996;39:2052-61.
98. Stegeman CA, Cohen Tervaert JW, Sluiter WJ, Manson WL, de Jong PE, Kallenberg CG. Association of chronic nasal carriage of Staphylococcus aureus and higher relapse rates in Wegener granulomatosis. Ann Intern Med 1994;120:12-7.
99. Stegeman CA, Tervaert JWC, de Jong PE, Kallenberg CGM. Trimethoprim–sulfamethoxazole (co-trimoxazole) for the prevention of relapses of Wegener's granulomatosis. N Engl J Med 1996;335:16-20.

Downloaded from www.nejm.org at UNIVERSITY HOSPITALS OF CLEVELAND on May 26, 2006 .
Copyright © 1997 Massachusetts Medical Society. All rights reserved.