Unexplained Weight Loss in Two Growth Hormone Deficient Adolescent Males

Cynthia Gordner[1], RN, BS, M. Rose D'Arcangelo[1, 2], MD

Penn State Hershey Children's Hospital[1], Penn State University College of Medicine[2]

Patient Demographics

Patient A: 15 ½ year old Caucasian male

Clinical Presentation/Diagnosis

Patient A has been followed in the pediatric endocrine clinic since age 18 months. He was diagnosed with growth hormone (GH) and thyroid deficiencies. GH was discontinued at age 15 years 1 month due to growth completion. He had an appendectomy 1 month prior to his routine endocrine follow-up visit, and complains of diminished energy level and a 15-lb weight loss despite adequate oral intake and absence of gastrointestinal symptoms. No acute illness has been noted by his pediatrician.

References

1. Molitch, M.E., Clemmons, D.R., Malozowski, S., Merriam, G.R., Shalet, S.M., Vance, M.L. (2006). Clinical Practice Guideline-Evaluation and treatment of adult growth hormone deficiency: An endocrine society clinical practice guideline. *The Journal of Clinical Endocrinology & Metabolism, 91*(5), 1621-1634. doi: 10.1210/jc.2005-2227

Past History

Patient A has the following history:

•Severe growth retardation as an infant and toddler

•Diagnosis of GH deficiency at age 18 months

•Treatment with growth hormone therapy at 0.3mg/kg/wk

•Diagnosis of hypothyroidism in the toddler period

•Maintained on levothyroxine 25 mcg from the time of diagnosis until discontinuation of GH

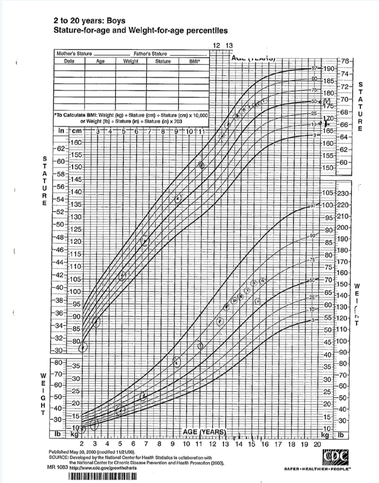

Evaluation

The following tests have been completed to evaluate patient A:

Test	Result
IGF-1	70 (201-609 ng/mL)
Thyroid function studies (off levothyroxine)	Normal
Fasting Glucose	80 (56-145 mg/dL)
Fasting Cortisol	21 (6.0-23.0 mcg/dL)
GH_{max} on insulin tolerance test	0.9 ng/dL
MRI	Empty sella
Bone age	16y6m @15y1m

Interventions

Patient A was evaluated for adult growth hormone deficiency, with IGF-1 and insulin tolerance test. Growth hormone was restarted at a transition dose of 0.03 mg/kg/day. Return evaluation following two months of growth hormone therapy revealed an 18-lb weight gain, and resumption of his normal energy levels. Levothyroxine was not resumed due to normal thyroid function studies without medication.

Patient Demographics

Patient B: 17 year old Caucasian male

Clinical Presentation/Diagnosis

Patient B has been followed in the endocrine clinic since 7 years of age with growth hormone deficiency. GH was discontinued six months prior to his visit due to poor compliance. Bone age was 14 years at 15 years 5 months. He reported a 20-lb weight loss and diminished energy level. He had not had changes in his medical regimen. No other acute illnesses were present.

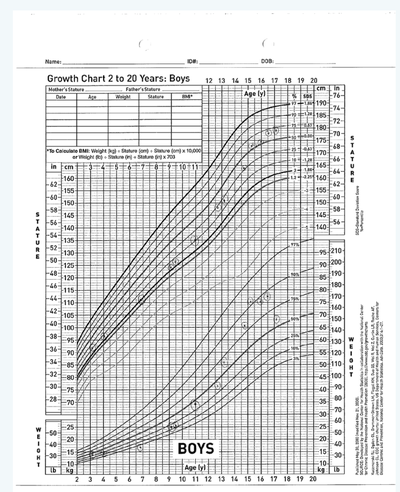

Past History

Patient B has a complicated medical history including:

•Fetal alcohol syndrome

•Failure to thrive

•Global developmental delay

•Attention deficit hyperactivity disorder

•Gastroesophageal reflux disease

•Eosinophilic esophagitis

•Nissen fundoplication

•Growth hormone deficiency diagnosed at age 7 years

Evaluation

The following tests have been completed to evaluate patient B:

Test	Result
IGF-1	129 (209-602 ng/mL
Thyroid function studies	Normal
Fasting Cortisol	21.5 (4.2-38.4)
GH_{max} on Insulin Tolerance Test	1.5 ng/mL
Repeat MRI	Normal

Interventions

Patient B was evaluated for adult growth hormone deficiency, with IGF-1 and insulin tolerance test. He was restarted on GH at a dose of 0.01 mg/kg/day. He has not seen the endocrinologist for follow-up visit since restarting GH therapy; however, a visit with the gastroenterologist 3 months after GH restart revealed a 19-lb weight gain. Phone conversation with the patient's parent revealed an improvement in his energy level.

Discussion

The usual presentation for adult GH deficiency is an increase in fat mass, and decrease in lean muscle mass, accompanied by weight gain, diminished energy levels, and decreased quality of life(1). The use of GH increases lipolysis, with a decrease in visceral fat with GH treatment(1). Both of these cases are not reflective of the usual presentation for adult GH deficiency. No reports of this phenomenon were found in the literature.